Adhesive Protocol for the Utilization of Aluminum Oxide Crown Restorations

Christof Schirra, DMD*

The ultimate objective of anterior tooth restoration is to achieve an aesthetic appearance that is in harmony with the natural dentition. It is often challenging to replicate the optical characteristics (ie, transparency and translucency) of a natural tooth without utilizing all-ceramic crown restorations, which may provide enhanced aesthetics and biocompatibility in comparison to metal-based treatment. This article demonstrates the use of all-ceramic technology with a contemporary adhesive procedure as a means to achieve improved aesthetic results in the restoration of the anterior dentition.

Key Words: adhesive, aesthetic, post, all-ceramic, cement

The optical characteristics evident in the natural dentition are a result of a unique transmission and reflection of light. It is the innate anatomy of the tooth structure that exhibits this translucency and makes the fabrication of a natural-appearing crown restoration a significant challenge.[1-6] Conventional materials and techniques used to achieve optimal aesthetics (eg, porcelain-fused-to-metal crowns with chamfer or shoulder margins[1]) utilize a reduced metal margin to accomplish this objective. The evolution of contemporary ceramic materials has resulted in the development of all-ceramic crowns that accurately replicate the natural dentition (Figures 1 and 2).[2,3,7] These all-ceramic systems are characterized by enhanced aesthetic properties and can be harmoniously integrated with the gingival tissues.[1-6]

The all-porcelain crown restoration simulates the natural mamelons, which decreases the distinction between the natural tooth and the crown. These aesthetic results can be achieved with various all-ceramic systems (eg, In-Ceram Spinell, Vident, Brea, CA; Procera, Nobel Biocare, Yorba Linda, CA; IPS Empress2, Ivoclar Williams, Amherst, NY). Although these materials are fabricated differently, they have demonstrated favorable physical and optical characteristics and long-term success.[4,8-12] Due to the three to four times greater flexural strength of aluminous ceramic materials, it has been suggested that they be used as a core material for fixed partial dentures.[2,13] Improved adhesive procedures have enabled the clinical success of these restorations and permitted the aesthetic enhancement of the maxillary anterior region.[13,14]

It is the high flexural strength of these systems that offers considerable advantages when all-ceramic crown restorations are cemented with either conventional zinc

Figure 1. Preoperative facial view of unaesthetic maxillary incisors. Note the endodontically treated and discolored maxillary left central incisor.

*Assistant Professor, Department of Operative Dentistry and Periodontology, Albert-Magnus University, Cologne, Germany; private practice, Düsseldorf, Germany.

Christof Schirra, DMD
Zietenstrasse 1
40476 Düsseldorf
Germany

Tel: (011) 49-211-498-0148
Fax: (011) 49-211-498-0149

phosphate or glass-ionomer cements. These materials are easily applied for subgingival tooth preparation, although reduced translucency often results in this situation due to the opacity of these cements (Figure 3).[6] In order to reduce the effect of the cement upon the translucency of the all-ceramic restoration, it is necessary to utilize an alternative means of facilitating the bonding procedure. This article demonstrates the use of adhesive bonding techniques that enables an aesthetic, biocompatible result to be achieved with all-ceramic technology (Figure 4).[15]

Preparation

It is necessary to consider various factors when preparing a tooth for an aesthetic restoration. In order to instill translucency and natural color in the vital and nonvital tooth, the restoration should be built up with a transparent composite filling material.[16] The use of a metal post to build up a nonvital tooth results in tooth discoloration, particularly at the gingival margin.[7,17,18] Consequently, it may prove advantageous to build up and stabilize a nonvital tooth using a zirconium post (eg, CeraPost, Brasseler USA, Savannah, GA; CosmoPost, Ivoclar Williams, Amherst, NY) or a light-conducting post (eg, Esthetic Post, Metalor Dental, North Attleborough, MA [in preparation]) prior to restoration with an all-ceramic material.[19] The light-conducting post has exhibited high fatigue strength and tensile strength due to its fiber structure. The elasticity of this post also appears similar to natural tooth dentin, which reduces the potential of tooth fracture.[19] The light transmission and conduction associated with the light-conducting post have also enabled restorative teams to achieve the increasing aesthetic demands of their patients (Figure 5).

Figure 2. Postoperative facial view of the definitive all-ceramic crown restoration. Note the significant aesthetic improvement, particularly in the light-conducting maxillary left central incisor.



Figure 3. Image depicts zinc phosphate cement (left), composite resin cement (center), and glass-ionomer cement (right).

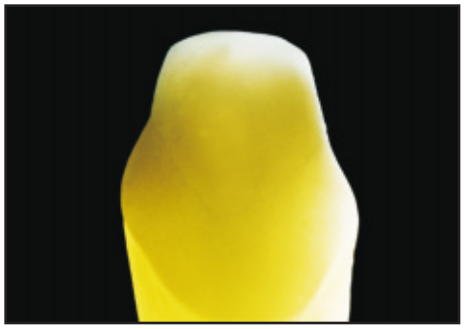

Figure 4. Appearance of an aluminum oxide ceramic core (In-Ceram Spinell, Vident, Brea, CA) viewed under transillumination.

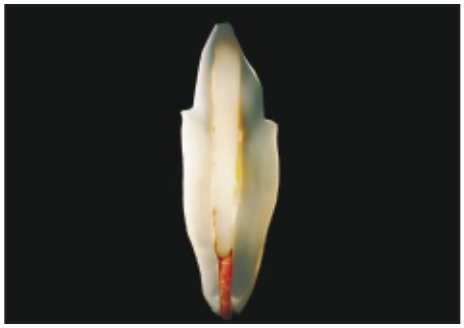

Figure 5. Transilluminated section of a natural tooth demonstrates the placement of the definitive aesthetic post. Note the brightened appearance of the tooth.

Adhesive Bonding

All-ceramic systems can generally be divided into two classifications: leucite-reinforced and alumina-reinforced materials. When performing cementation, it is important for the clinician to know whether or not the ceramic core can be etched. Alumina-reinforced materials can only be sandblasted using 110 μm alumina particles at

Figure 6. Preoperative facial view of a 19-year-old male patient with a nonvital discolored maxillary left central incisor.

Figure 7. A drill was utilized to shape the root canal of the tooth.

Figure 8. The light-conducting post is tried in to verify fit in the prepared root canal.

2.5 bars pressure to achieve an increase of micromechanical retention. Numerous investigations have established that the optimal means of performing cementation was to sandblast the core with alumina particles prior to bonding with a self-curing cement (eg, Panavia 21 TC, J. Morita, Tustin, CA).[20-25] These studies demonstrated that silanization was ineffective with alumina-reinforced restorations and that hydrofluoric acid decreased the bond strength in comparison to leucite-reinforced systems (eg, IPS Empress, Ivoclar Williams, Amherst, NY).

Case Presentation

A 19-year-old male patient presented for the restoration of a discolored maxillary left central incisor (Figure 6). Upon clinical and radiographic examination, it was determined that the tooth was nonvital. A comprehensive restorative plan was formed to first stabilize the endodontically treated incisor; the tooth would subsequently be restored with an all-ceramic crown restoration. The patient consented to the plan and treatment was initiated.

In the primary phase of treatment, a conical light-conducting post (eg, Esthetic Post, Metalor Dental, North Attleborough, MA [in preparation]) would be placed for stabilization and to prevent the fracture of the endodontically treated tooth.[2,26-28] The preparation for this replacement was essentially similar to that performed for zirconium posts.[7,17] Utilizing a radiograph, the correct diameter of the post was determined. In order to minimize the potential of root fracture, the length of the post was established 5 mm to 6 mm shorter than the root apex. Prior to the preparation of the root canal, a 90° shoulder margin was established, and gutta-percha points were removed with a drill (Largo #2, Metalor Dental, North Attleborough, MA). The root canal was subsequently formed using a preshaping drill (Figure 7), and the post was seated in the canal and evaluated for proper fit (Figure 8). The clinician ensured that the fit was not too tight, which could have prevented complete sealing during cementation. Once fit had been assessed, the length of the post was reduced.

The root canal was etched with 33% phosphoric acid (Etching Agent V, J. Morita, Tustin, CA) for 15 seconds,

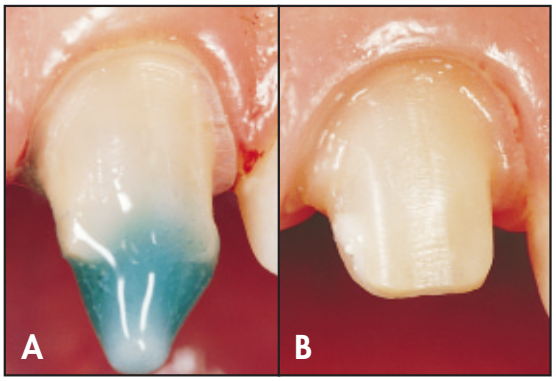

Figure 9A. Phosphoric acid was applied for 15 seconds, and the canal was rinsed and dried. Following the application of a dentin bonding agent, the post was cemented, and a blocking gel was used. 9B. The core buildup is completed and prepared with 90° shoulder margins.

rinsed, and thoroughly dried. Following the application of a dental bonding agent (Clearfill New Bond, J. Morita, Tustin, CA) to the tooth and the post, the latter was cemented with a chemical composite resin (Panavia Ex, J. Morita, Tustin, CA) (Figure 9A). The core buildup was completed utilizing a hybrid composite material (eg, Herculite XRV, Kerr/Sybron, Orange, CA; Charisma, Heraeus Kulzer, South Bend, IN), and a 90° shoulder preparation was completed (Figure 9B).[29]

Prior to the final restorative phase, a rubber dam should be applied to the prepared tooth and adjacent teeth to facilitate control of moisture and achieve proper isolation. In the maxillary region, however, the use of a rubber dam may cause injury to the gingival margin. An alternative method achieves isolation using an unsoaked, nonimpregnated retraction cord (Ultrapak, Ultradent Products, South Jordan, UT) (Figure 10). This prevents leakage of the gingival fluids and reduces the danger that may occur during cementation if the adhesive cannot be compressed and remain in the marginal sulcus.

Following removal of the provisional restoration, the tooth surface was cleansed with pumice to remove any remaining debris and prepare for the selective "total etch" procedure. Phosphoric acid (33%, Etching Agent V, J. Morita, Tustin, CA) was applied to the enamel for 30 seconds and dentin layers for 10 to 15 seconds (Figure 11A). The tooth surfaces were then rinsed with water for 30 seconds and thoroughly dried again (Figure 11B).[30] The enamel and dentin bonding agent was subsequently applied to the tooth and gently air thinned (Figure 12). The chemically cured cement (Panavia 21 TC, J. Morita, Tustin, CA) was prepared simultaneously to reduce the duration of the chairside procedure and then applied with a small brush to the cavity of the restoration.

The definitive all-ceramic crown restoration (In-Ceram Spinell, Vident, Brea, CA) was seated with a fine instrument to gently remove excess cement and to ensure proper placement. In order to prevent oxygen from compromising the adhesive procedure, an oxygen-blocking gel (Oxyguard II, J. Morita, Tustin, CA) was applied to the occlusal surface of the restoration. Since a chemically cured resin was utilized for cementation, this procedure was completed expeditiously. Following a period of 6 minutes, the cement had hardened, and the clinician was able to rinse away the oxygen-inhibiting gel with

Figure 10. Occlusal view demonstrates the placement of the retraction cord, which was placed circumferentially around the preparation.

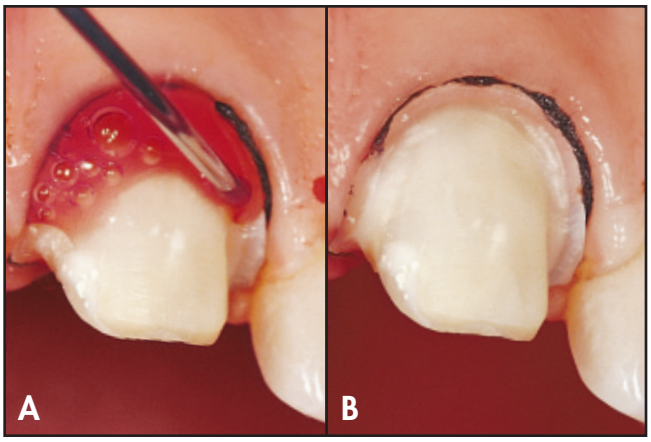

Figure 11A. The enamel was etched with 33% phosphoric acid according to the "total-etch" procedure. 11B. Facial view exhibits the milky appearance of the etched enamel surfaces.

Figure 12. Facial view demonstrates the application of the enamel and dentin bonding agent.

Figure 13. Following the removal of an oxygen-blocking gel, the retraction cord was removed with a probe.

Figure 14. Facial view of the restoration following cementation. The inflamed gingival margin is clearly evident.

Figure 15. Facial view of the definitive all-ceramic crown restoration 3 weeks postcementation. Note the significant aesthetic improvement that has been achieved.

water and clean the surfaces of the restoration. Excess cement and the retraction cord were subsequently removed with a probe and a fine-tipped instrument (Figure 13). The patient's occlusion and articulation were evaluated and determined to be acceptable. Although the gingival margin had an inflamed appearance immediately following cementation (Figure 14), this condition had been resolved three weeks postoperatively (Figure 15). This result satisfied the aesthetic objectives of the patient, who was appointed for periodic clinical and radiographic examination to monitor the success of the restorative procedure.

Conclusion

Innovations in all-ceramic crown systems have permitted the fabrication of core materials with optical characteristics (ie, translucency, aesthetics) that replicate those of the natural dentition. The utilization of adhesive bonding (ie, composite resin cements) allows the all-ceramic restorations to maintain natural transparency and translucency in a manner that cannot be achieved with conventional opaque cements, which can reduce the chroma of the restoration. The aesthetics of all-ceramic technology can also be enhanced by the use of a light-conducting post during the preparation phase. While the use of prefabricated zirconium or light-conducting posts can be combined with contemporary adhesive technology to facilitate cementation directly in the root canal, the long-term success of such restorations warrants additional exploration.

Acknowledgment

The author mentions his gratitude to Claude Sieber, Basel, Switzerland, for the fabrication of the all-ceramic restorations featured in this article, and to Jayne Krentz for assistance in the preparation of this article.

References

1. Paul SJ, Pietrobon N. Aesthetic evolution of anterior maxillary crowns: A literature review. Pract Periodont Aesthet Dent 1998; 10(1):87-94.
2. Claus H. Vita In-Ceram, a new procedure for preparation of crown and bridge framework. Quintessenz Zahntech 1990; 16(1):35-46.
3. Paul SJ, Pietrobon N, Schärer P. The new In-Ceram Spinell system — A case report. Int J Periodont Rest Dent 1995;15(16): 520-527.
4. Hegenbarth EA. Procera aluminium oxide ceramics: A new way to achieve stability, precision and esthetics in all-ceramic restorations. Quint Dent Technol 1996;19:21-34.

5. Sieber C, Thiel N. Spinell/Luminary porcelain: Natural light optics for anterior crowns. Quint Dent Technol 1996;19:43-49.
6. Sieber C. A key to enhancing natural esthetics in anterior restorations: The light-optical behavior of Spinell Luminaries. J Esthet Dent 1996;8(3):101-106.
7. Kern M, Simon MPH, Strub JR. Clinical evaluation of all-ceramic zirconia posts. A pilot. J Dent Res 1997;76:293(Abstract No. 2234).
8. Hölsch W, Kappert HF. Festigkeitsprüfung von vollkeramischem Einzelzahnersatz für den Front - Und Seitenzahnbereich. Dtsch Zahnärztl Z 1992;47:621-623.
9. Kappert HF, Knode H, Schultheiss R. Strength of the In-Ceram system under mechanical loads and thermocycling in artificial saliva. Dtsch Zahnärztl Z 1991;46(2):129-131.
10. Kappert HF, Altvater A. Field study on the accuracy of fit and the marginal seal of In-Ceram crowns and bridges. Dtsch Zahnärztl Z 1991;46(2):151-153.
11. Prestipino V, Ingber A, Kravitz J. Clinical and laboratory considerations in the use of a new all-ceramic restorative system. Pract Periodont Aesthet Dent 1998;10(5):567-576.
12. Pröbster L. Survival rate of In-Ceram restorations. Int J Prosthodont 1993;6(3):259-263.
13. Sadoun M. All-ceramic bridges with the slip casting technique. Presented at the 7th International Symposium on Ceramics. Paris, France; 1988.
14. Chen C, Schärer P. Zemente und Zementieren. Ein klinisches Kompendium. Band Auflage, Zürich; 1996.
15. Malament KA, Grossman DG. Bonded vs non-bonded Dicor crowns: Four-year report. J Dent Res 1992;71:321(Abstract No. 1720).
16. Paul SJ, Schärer P. Adhäsivaufbauten für Vollkeramikkronen. Schweiz Monatsschr Zahnmed 1996;106:368-374.
17. Meyenberg KH, Lüthy H, Schärer P. Zirconia posts: A new all-ceramic concept for nonvital abutment teeth. J Esthet Dent 1995;7(2):73-80.
18. Koutayas SO, Kern M. All-ceramic posts and cores: The state of the art. Quint Int 1999;30:383-390.
19. Schirra CH. The esthetics of the anterior teeth with the In-Ceram-Spinell system. The advantages and clinical procedure in the care of the anterior teeth using In-Ceram-Spinell crowns. Schweiz Monatsschr Zahnmed 1998;108(7):662-679.
20. Kern M, Thompson VP. Sandblasting and silica coating of a glass-infiltrated alumina ceramic: Volume loss, morphology, and changes in the surface composition. J Prosthet Dent 1994; 71(5):453-461.
21. Kern M, Thompson VP. Bonding to glass infiltrated alumina ceramic: Adhesive methods and their durability. J Prosthet Dent 1995;73(3):240-249.
22. Chiche G. Application of microetching to all-ceramic crown techniques. Pract Periodont Aesthet Dent 1998;10(5):626.
23. Edelhoff D, Marx R. Adhäsion zwischen Vollkeramik und Befestigungskomposit nach unterschiedlicher Oberflächenbehandlung. Dtsch Zahnärztl Z 1995;50:112-117.
24. McLaren EA, Sorensen JA. Composite cements to In-Ceram Spinell shear bond strength. J Dent Res 1995;74:422.
25. Kern M, Wegner SM. Bonding to zirconia ceramic: Adhesion methods and their durability. Dent Mater 1998;14:64-71.
26. Trabert KC, Caput AA, Abou-Rass M. Tooth fracture — A comparison of endodontic and restorative treatments. J Endod 1978;4(11):341-345.
27. Helfer AR, Melnick S, Schilder H. Determination of the moisture content of vital and pulpless teeth. Oral Surg Oral Med Oral Pathol 1972;34(4):661-670.
28. Vire DE. Failure of endodontically treated teeth: Classification and evaluation. J Endodont 1991;17(7):338-342.
29. Chiche G, Pinault A. Esthetics of Anterior Fixed Prosthodontics. Carol Stream, IL: Quintessence Publishing; 1994.
30. Van Meerbeek B, Braem M, Lambrechts P, Vanherle G. Dentinhaftung: Mechanismen und klinische Resultate. Dtsch Zahnärztl Z 1994;49:977-984.

Continuing Education (CE) Exercise No. 31

31
CONTINUING EDUCATION

NEW YORK UNIVERSITY
College of Dentistry
Center for Continuing Dental Education
New York City, NY

To submit your CE Exercise answers, please use the answer sheet found within the CE Editorial Section of this issue and complete as follows: 1) Identify the article; 2) Place an X in the appropriate box for each question of each exercise; 3) Clip answer sheet from the page and mail it to the CE Department at Montage Media Corporation. For further instructions, please refer to the CE Editorial Section.

The 10 multiple-choice questions for this Continuing Education (CE) exercise are based on the article "Adhesive protocol for the utilization of aluminum oxide crown restorations" by Christof Schirra, DMD. This article is on Pages 955-960.

Learning Objectives:

This article discusses the utilization of all-ceramic technology with contemporary adhesive procedures to achieve improved aesthetic results in anterior dentition restoration. Upon reading and completing this exercise, the reader should:

- Identify various factors necessary to facilitate dentin preparation for aesthetic restoration.
- Develop an understanding of various adhesive protocols to achieve successful definitive restorations.

1. Aluminous ceramic materials have been utilized as a core material for fixed partial dentures because:
a. They possess higher flexural strength.
b. The restorations have demonstrated clinical success.
c. The maxillary anterior region is aesthetically enhanced.
d. All of the above.

2. What is necessary for increasing the micro-mechanical retention in alumina-reinforced materials?
a. Utilize silanization techniques.
b. Sandblast the materials using 110 μm alumina particles at 2.5 bars pressure.
c. Increase the bond strength with hydrofluoric acid.
d. Use a light-cure cement.

3. Prior to the final restorative phase, a rubber dam should be applied in order to accomplish each of the following objectives EXCEPT:
a. Facilitate control of moisture.
b. Prevent leakage of gingival fluids.
c. Achieve proper isolation.
d. Protect the maxillary gingival margin.

4. Zirconium or light-conducting posts are utilized for each of the following reasons EXCEPT:
a. They reduce the expense of restoration.
b. They exhibit high fatigue strength.
c. They exhibit high tensile strength.
d. They reduce the probability of tooth fracture.

5. Innate dentin anatomy exhibits which of the following properties:
a. Translucency.
b. Opaqueness.
c. Multiple hues.
d. Subtle discolorations.

6. Tooth discoloration during nonvital restoration occurs when:
a. A zirconium post is utilized prior to restoration.
b. Transparent composite filling material is utilized to build up a nonvital tooth.
c. Metal posts are utilized to build up a nonvital tooth.
d. A light-conducting post is utilized prior to restoration.

7. In this article, what preventive measure was taken to prevent potential root fracture?
a. Creation of a post 5 mm to 6 mm shorter than the root apex.
b. Removal of gutta-percha points with a drill.
c. Establishment of a 90° shoulder margin.
d. Cementation of the post with a chemically composite resin.

8. Adhesion of aluminium oxide crown restorations can be compromised by:
a. Admission of oxygen through the occlusal surface.
b. Application of excess cement.
c. An inflamed gingival margin.
d. Leakage of gingival fluid.

9. Conventional zinc phosphate or glass-ionomer cements are utilized for all-ceramic crown restorations because:
a. These materials enhance the elasticity of the restoration.
b. These cements increase translucency.
c. These cements are easily applied for subgingival tooth preparation.
d. The cements create a better seal.

10. Once the provisional restoration is removed, the tooth surface was cleansed with pumice to:
a. Maintain transparency and translucency.
b. Reduce the duration of chairtime procedure.
c. Remove residual debris and prepare for the "tooth etch" procedure.
d. Prevent the fracture of the endodontically treated tooth.